
Breakthrough Advancement in Ablation Technology

Andy C. Kiser, M.D.*, J. Paul Mounsey, B.M. B.Ch.*, Hayden R. Pappas, M.D.*

INTRODUCTION

The Estech COBRA Fusion™ Ablation System was developed to provide superior epicardial ablation performance on the beating heart. Current ablation devices have significant limitations that prevent effective use in creating full-thickness (transmural) lesions. Bipolar ablation clamps are a widely accepted means to create transmural lesions of the left and right pulmonary veins (PVs). However, when bipolar clamps are used in an epicardial beating-heart approach, they cannot create linear lesions between the PVs. Due to their size and shape, bipolar clamps are also not particularly well suited for minimally invasive procedures, adding significant procedural complexity to yield only a limited lesion set.

Non-clamping devices commonly used on the epicardial surface fail to make consistent transmural lesions for a number of technical reasons; mostly due to poor and/or inconsistent tissue contact and the inability to overcome the heat sink at the endocardial surface. These devices, which are often used to make epicardial linear connecting lesions in conjunction with bipolar ablation clamps, have demonstrated limited effectiveness in both animal and human studies.¹⁻⁶

The new Estech COBRA Fusion was designed to form reliable epicardial transmural lesions and overcome the technical limitations of earlier devices. To evaluate this new ablation technology, we performed rigorous porcine animal studies during which the new ablation technology was applied to the epicardium of the beating heart. Following the ablation procedure, the animals were euthanized and the lesions were evaluated to determine the effectiveness of lesion creation.

In addition, we report early clinical results of the COBRA Fusion in patients to examine the ability to successfully create the “box” lesion pattern around the pulmonary veins. Following completion of the surgical epicardial ablation via a right thoracoscopy, we assessed the lines of conduction block using endocardial voltage mapping to determine if the posterior left atrium was electrically isolated from the rest of the atrium.

From the *Division of Cardiothoracic Surgery and Electrophysiology, UNC Center for Heart and Vascular Care, Chapel Hill, NC, USA

Disclosure: Dr. Kiser is a speaker and consultant for Estech. Dr. Mounsey is a speaker for Estech.

MATERIALS AND METHODS

Ablation Technology: The COBRA Fusion Surgical Ablation System is the first device of its kind. It combines intuitive temperature controlled radiofrequency (TCRF) with proprietary Versapolar™ technology – the only platform that is capable of delivering both bipolar and monopolar radiofrequency (RF) energy with one device. The COBRA Fusion utilizes a unique suction design with innovative electrode positioning that enables consistent tissue contact and eliminates the inherent heat sink effect of a beating heart. A cross-section of the device (Figure 1) illustrates the design concept. Vacuum gently draws tissue into the device, removing the targeted tissue from exposure to the heat sink of endocardial blood flow (Figure 2). Electrodes mounted in the opposing sidewalls of the suction stabilizer provide sequential bipolar and monopolar ablation of the shielded tissue utilizing Estech’s patented TCRF. The COBRA Fusion ablation devices (Figure 3) are available in two lengths: 50mm and 150mm long (COBRA Fusion 50 and COBRA Fusion 150 ablation probes, respectively). In operation, the device is a flexible curvilinear catheter designed to produce epicardial linear lesions anywhere on a beating heart with the benefits of endocardial blood exclusion. The company recommends that all epicardial lesions made with the COBRA Fusion devices use both bipolar and monopolar modes of RF ablation in series, with the bipolar mode used first. Recommended (and factory set) ablation parameters for each application of RF energy are: 60 second ablation time; 70°C set temperature; and maximum power setting of 50 Watts/electrode.

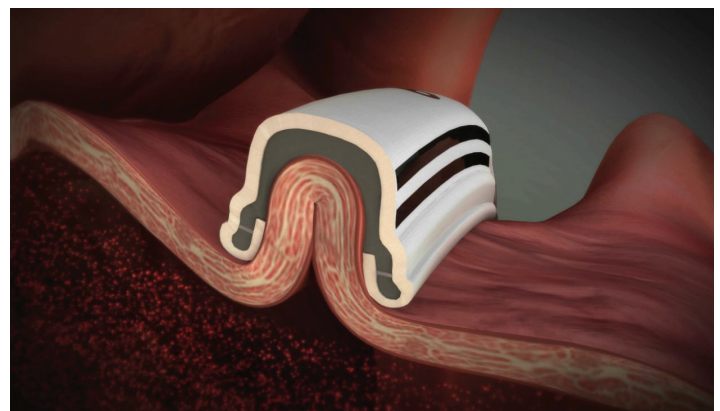


Figure 1: Design concept for the COBRA Fusion™ ablation device. The cross section illustrates how vacuum within the cavity of the suction stabilizer draws tissue into the device. The full wall thickness is drawn into the device between the bipolar pair of ablation electrodes mounted on opposing sides of the interior aspect of the suction stabilizer.

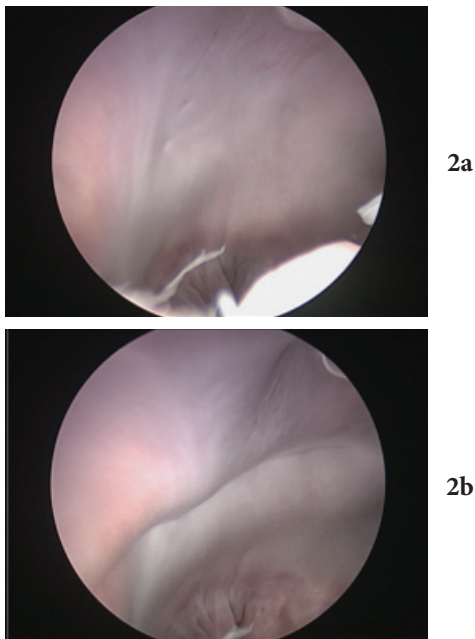


Figure 2: Example of the COBRA Fusion ablation device pre- and post-vacuum suction stabilization. Pictures were taken from inside the left atrium of ex-vivo porcine heart. **Figure 2a:** Fluid filled atrium shows atrial wall prior to COBRA Fusion ablation device application, **Figure 2b:** Selected atrial tissue incorporated into device, suction held at -500mmHg during ablation.

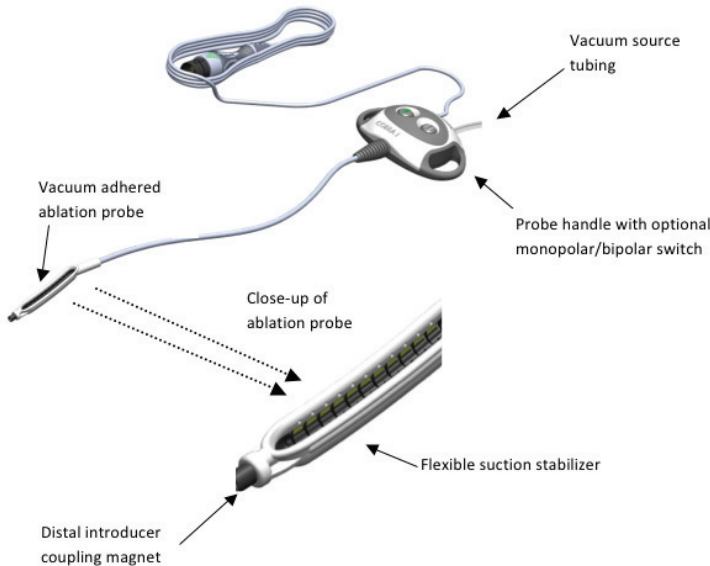


Figure 3: The COBRA Fusion ablation devices come in two lengths: 50mm and 150mm long. The COBRA Fusion 50 ablation device has two selectable electrodes and the COBRA Fusion 150 ablation device has 6 selectable electrodes.

Animal Lesion Study: Lesions were applied to the epicardial surfaces of three 100-Kg+ porcine models via transverse mediansternotomy. The COBRA Fusion 50 ablation device, with two-electrodes, was used per Estech's Instructions For Use and lesions were created. An application of RF energy was performed at each site, first in bipolar mode, then in monopolar mode. Each lesion was created using the following settings: 50W/electrode, 70°C for 60 seconds, with -500mmHg vacuum applied to the suction stabilizer. Transmurality of lesions were verified clinically by acute conduction block assessment and histologically by gross tissue staining using 2,3,5-triphenyl-tetrazolium chloride (TTC) and subsequent cross-section evaluation.

RF energy was applied to right (RAA) and left atrial appendages (LAA) and the Superior Vena Cava (SVC) to the Inferior Vena Cava (IVC). More specifically, the anterior/lateral face of the LAA was ablated in an attempt to isolate the tip of the LAA. Isolation of RAA tip was attempted by ablating both the anterior and posterior aspects of the appendage. The lesion sites selected ensured that differing tissue qualities were tested; the locations chosen demonstrated use of the device over thin, smooth tissue with higher endocardial blood flow as well as use of the device over thick, irregular, trabeculated tissue. We created 5cm lesions by employing both electrodes in the 50mm device. Following the procedure, conduction block was confirmed, TTC was injected, and the animal was euthanized and tissue harvested for examination. Each treatment site was photographed to show epicardial and endocardial surfaces of the ablated regions (Figure 4).

The samples were then placed in TTC to better visualize the dimension of the lesions created. Each lesion was transected at 5mm intervals to assess lesion depth and to determine if the lesion was transmural at the transected sites. For LAA and RAA lesion assessment, the atrial wall was defined to extend from the epicardium to the endocardium; trabeculae that were near to a particular wall of an appendage but separate from the appendage wall, such as is shown in Figure 5, were excluded from the transmural evaluation.

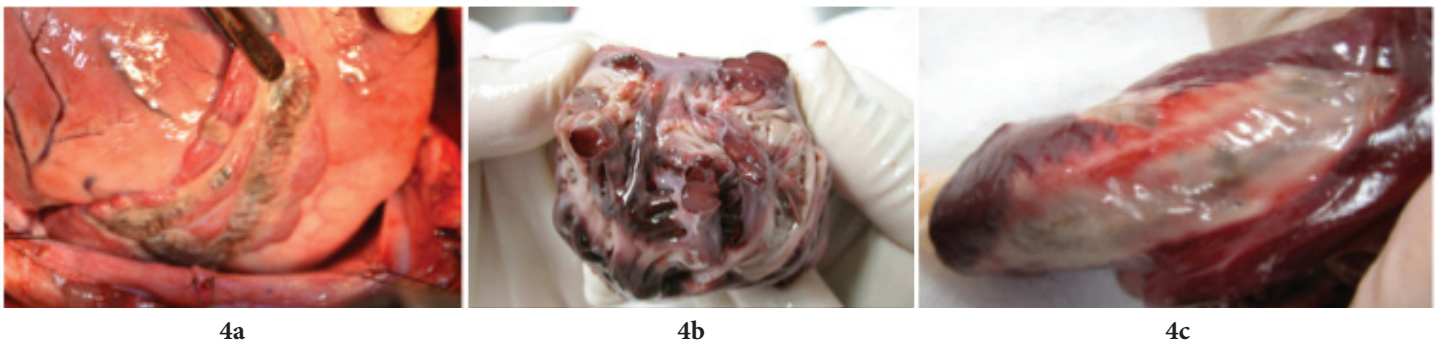


Figure 4a: Epicardial lesions on LAA. **Figure 4b:** Endocardial view of LAA showing continuous transmural lesion isolating tip (center) from base. **Figure 4c:** Endocardial view of SVC showing continuous transmural lesion along SVC to IVC.

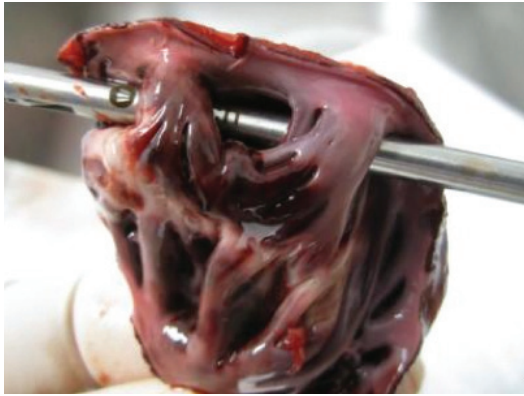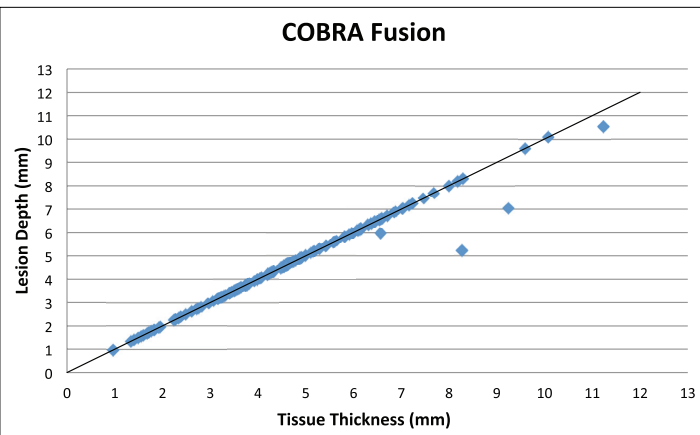


Figure 5: Trabeculae in the porcine LAA are commonly separated from the LAA wall, as shown in this example. In such cases the detached trabeculae are removed to enable lesion depth on the LAA wall to be assessed accurately. Such trabeculae are not present in humans.

ANIMAL RESULTS

Conduction block was achieved following ablation of the RAA and LAA at a maximum pacing threshold of 20mA in all three animals. Gross examination of these lesions demonstrated obvious transmural. Gross examination of the endocardial surface of this tissue revealed large separated trabeculae in two animals which were not effectively ablated because their structure prevented those large bundles of muscle fibers from being drawn into the device. Such trabeculae are not representative of human tissue to be ablated during a cardiac ablation procedure.

Transmurality was achieved at 137/141 evaluation sites, which corresponds to full thickness lesion achieved at 97.2% of the locations chosen to provide challenging ablation conditions. Graph 1 demonstrates the lesion depth achieved versus tissue wall thickness. Points that fall on the line of identity indicate lesion sites that were full thickness. Transmurality was observed at 100% of sites at which tissue wall thickness was less than 6mm. Full thickness lesions were also commonly observed in thick tissue; 91% of lesions applied to tissue walls that were 6mm or more in thickness were transmural.



Graph 1: Graphic comparison of lesion depth versus wall thickness for all 141 sections through the epicardial lesions made with the COBRA Fusion 50 ablation probe. All points on the identity line (lesion depths and tissue thickness equal) represent full thickness lesions at the evaluated tissue section.

EARLY CLINICAL RESULTS

As part of the early clinical evaluation of the COBRA Fusion ablation device, we examined the ability to successfully create the “box” lesion pattern around the pulmonary veins. Upon completion of the surgical epicardial ablation via right thoracoscopy, patients were transferred to the electrophysiology laboratory. After double transseptal catheterization under ultrasound guidance and using standard techniques, a detailed voltage map of the left atrium was constructed using EnSite NaVx hardware and software (St. Jude Medical Inc., St. Paul, Minn.). The posterior left atrium was electrically isolated from the rest of the atrium at the completion of epicardial ablation procedures. The example in Figure 6 shows an endocardial voltage map of the left atrium of a patient immediately status-post epicardial ablation around the pulmonary vein pedicle with the COBRA Fusion ablation device. Areas in gray had a recorded voltage of less than 0.1mV. Areas in purple had a voltage of more than 0.5 mV. It is clear from Figure 6a that the posterior wall and pulmonary veins showed no electrical activity whereas the anterior wall and left atrial appendage were electrically active (Figure 6b). This patient was in a peri-mitral atrial flutter after the epicardial portion of the operation and restoration of sinus rhythm required construction of a linear ablation between the left inferior pulmonary vein and the mitral valve annulus.

“We have never seen electrical isolation like this from an endoscopic epicardial ablation device.” remarks Dr. Mounsey.

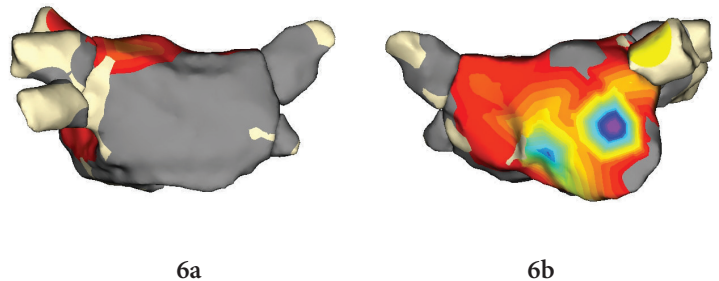


Figure 6: Electroanatomical map of the posterior (a) and anterior (b) left atrium. Areas in grey record voltage amplitude <0.1mV; Areas in purple record voltage amplitude >0.5mV. **Figure 6a:** Demonstrates an electrically silent posterior left atrium following the epicardial “box” lesion pattern creation with the COBRA Fusion ablation device. **Figure 6b:** Demonstrates the electrical activity of the anterior left atrium after the surgical ablation.

DISCUSSION

Devices designed to make epicardial linear lesions on the beating heart have often performed poorly, even in the well-controlled conditions provided in animal studies. Shown in Figure 7 is the performance of the most commonly used device for creating linear epicardial connecting lesions, AtriCure® Coolrail.⁵ When compared to the COBRA Fusion, the AtriCure Coolrail is less effective at equivalent tissue thickness when used epicardially on the beating porcine heart for all tissue wall thicknesses and Coolrail ablation durations. As demonstrated by the outliers at less than

6mm seen in Figure 7, the Coolrail device is poorly effective when placed over thin tissue, such as near the inferior or superior vena cava. In a recent abstract presented at the International Society of Minimally Invasive Cardiothoracic Surgery (ISMICS), Dr. Damiano's laboratory reported that transmural lesions were achieved in only 24% of lesions when the AtriCure device was applied near the SVC or IVC region of the heart.⁶ Thin tissue represents a significant impediment to transmural lesion formation since the endocardial blood flow rapidly cools the targeted tissue. The COBRA Fusion overcomes this challenge by excluding the endocardial blood flow with the vacuum stabilization. The COBRA Fusion ablation device achieved 100% transmural lesions at those sites of thin tissue (≤ 6 mm). The COBRA Fusion also reliably created transmural lesions on thick tissue due to its Versapolar™ technology, employing both bipolar and monopolar RF energy. While bipolar ablation is more effective in creating transmural lesions in thin tissue, monopolar ablation provides the deepest lesion formation enabling the COBRA Fusion to perform well under all tissue thicknesses.

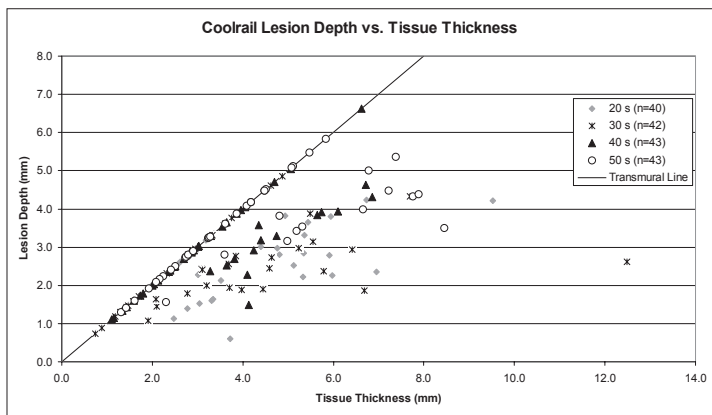


Figure 7: Lesion depth is plotted against tissue thickness for each cross section examined for the Coolrail device. Transmural lesions fall on the line of identity.⁵

CONCLUSION

This report documents the experimental and clinical successful use of Estech's novel epicardial ablation device, the COBRA Fusion, in animals and in early clinical experience. The device is capable of creating linear and transmural lesions on a beating porcine heart. The lesions demonstrate conduction block and effectively isolate desired regions of the heart of patients undergoing epicardial ablation. The use of this device may lead to improved clinical outcomes by leveraging the proven principles of bipolar ablation technology with an ability to create linear ablation lines thus enabling the creation of a comprehensive ablation pattern on a beating heart.

REFERENCES

1. Schuessler RB, Lee AM, Melby SJ, et al. Animal studies of epicardial atrial ablation. *Heart Rhythm*. 2009;6:S41-45.
2. Doll N, Kornherr P, Aupperle H, et al. Epicardial treatment of atrial fibrillation using cryoablation in an acute off-pump sheep model. *Thorac Cardiovasc Surg*. 2003;51:267-273.
3. Masroot S, Jahnke ME, Carlisle A, et al. Endocardial Hypothermia and Pulmonary Vein Isolation with Epicardial Cryoablation in a Porcine Beating Heart Model. *J Thorac Cardiovasc Surg* 2008;135:1327-1333.
4. Pozzoli A, Benussi S, Anzil F, et al. Electrophysiological efficacy of Epicor high-intensity focused ultrasound. *EUR J Cardiothoracic Surg* 2012; 42:129-134.
5. Lee AM, Aziz A, Sakamoto SI, et al. Epicardial Ablation on the Beating Heart: Limited Efficacy of a Novel, Cooled Radiofrequency Ablation Device. *Innovations* 2009;4:86-92.
6. Watanabe Y, Weimer T, Kazui T, et al. Factors Affecting the Efficacy of Epicardial Ablation Using a Cooled Radiofrequency Device. *Innovations* 2012; 7:128.

REGULATORY DISCLAIMER

The Estech COBRA Fusion Ablation System is intended to ablate cardiac tissue during cardiac surgery using radiofrequency (RF) energy when connected directly to the Estech Electrosurgical Unit (ESU).

The Estech COBRA Fusion 50 may be used for temporary cardiac pacing, sensing, recording and stimulation during the evaluation of cardiac arrhythmias during surgery when connected to a temporary external cardiac pacemaker or recording device.

The Estech ablation products are not approved for the treatment of AF in the U.S. Estech has received conditional Investigational Device Exemption (IDE) approval from FDA to begin enrollment in a clinical trial to support a PMA submission to obtain a specific atrial fibrillation indication in the U.S. for several products. In Europe, the Estech COBRA RF ablation products are CE marked with an indication for the treatment of atrial fibrillation.